

Hypoxia and Amino Acid Imaging of High-Grade Glioma

^{18}F -FAZA PET/CT and ^{11}C -Methionine PET/MRI

Paola Mapelli, MD,*† Federico Fallanca, MD,† Paola Scifo, PhD,† Maurizio Barbera, MD,‡ Antonella Castellano, MD,*‡ Valentino Bettinardi, MSc,† Elena Incerti, MSc,† Luigi Gianolli, MD,† Nicoletta Anzalone, MD,*‡ and Maria Picchio, MD*†

Abstract: In the present case, we report the first experience of a patient with high-grade glioma who underwent dual ^{18}F -FAZA PET/CT imaging for intratumoral hypoxia assessment, before treatment, and for therapy monitoring in the suspicious of recurrence, as part of a clinical research protocol. In addition, despite the diagnosis of glioblastoma, the patient at 3 years from diagnosis was alive and underwent ^{11}C -methionine simultaneous PET/MRI for disease monitoring after treatment, showing stability of disease. The multitracers capability of PET in assessing different and complementary metabolic features along with the use of a last-generation scanner as PET/MRI in brain oncology are here enlighten.

Key Words: ^{18}F -FAZA, ^{11}C -Methionine, PET/MRI, glioma, PET/CT
(*Clin Nucl Med* 2020;45: e290–e293)

Received for publication September 18, 2019; revision accepted February 16, 2020. From the *Vita-Salute San Raffaele University; †Nuclear Medicine Department, and ‡Neuroradiology Unit and CERMAT, IRCCS San Raffaele Scientific Institute, Milan, Italy.

All procedures performed in studies involving human participants were in accordance with the ethical standards of the institutional and/or national research committee and with the 1964 Helsinki Declaration and its later amendments or comparable ethical standards. Informed consent was obtained from the participant included in the study.

Conflicts of interest and sources of funding: M.P. received a GE Healthcare travel meeting support not related to the work. The other authors have no conflicts of interest to declare.

Correspondence to: Maria Picchio, MD, Vita-Salute San Raffaele University, Department of Nuclear Medicine, IRCCS San Raffaele Scientific Institute, Via Olgettina 60, 20132, Milan, Italy. E-mail: picchio.maria@hsr.it.

Copyright © 2020 Wolters Kluwer Health, Inc. All rights reserved.

ISSN: 0363-9762/20/4506–e290

DOI: 10.1097/RLU.00000000000003028

ACKNOWLEDGMENTS

The present work was supported by the Italian Association for Cancer Research (grant IG 2014 Id.1524; EudraCT: 2015-000679-28). Signa PET/MRI system (GEMS, Waukesha, WI) used in the present work has been purchased with funding from Ministero della Salute.

REFERENCES

1. Abd-Ellah MK, Awad AI, Khalaf AAM, et al. A review on brain tumor diagnosis from MRI images: practical implications, key achievements, and lessons learned. *Magn Reson Imaging*. 2019;61:300–318.
2. Anzalone N, Castellano A, Cadioli M, et al. Brain gliomas: multicenter standardized assessment of dynamic contrast-enhanced and dynamic susceptibility contrast MR images. *Radiology*. 2018;287:933–943.
3. Mapelli P, Bettinardi V, Fallanca F, et al. ^{18}F -FAZA PET/CT in the preoperative evaluation of NSCLC: comparison with ^{18}F -FDG and immunohistochemistry. *Curr Radiopharm*. 2018;11:50–57.
4. Mapelli P, Incerti E, Fallanca F, et al. Concomitant lung cancer and gastrointestinal stromal tumor: first report of hypoxia imaging with ^{18}F -FAZA PET/CT. *Clin Nucl Med*. 2017;42:e349–e351.
5. Mapelli P, Incerti E, Bettinardi V, et al. Hypoxia ^{18}F -FAZA PET/CT imaging in lung cancer and high-grade glioma: open issues in clinical application. *Clin Transl Imaging*. 2017;5:389–397.
6. Mapelli P, Zerbetto F, Incerti E, et al. ^{18}F -FAZA PET/CT hypoxia imaging of high-grade glioma before and after radiotherapy. *Clin Nucl Med*. 2017;42: e525–e526.
7. Kim D, Chun JH, Kim SH, et al. Re-evaluation of the diagnostic performance of ^{11}C -methionine PET/CT according to the 2016 WHO classification of cerebral gliomas. *Eur J Nucl Med Mol Imaging*. 2019;46:1678–1684.
8. Preibisch C, Shi K, Kluge A, et al. Characterizing hypoxia in human glioma: a simultaneous multimodal MRI and PET study. *NMR Biomed*. 2017;30:e3755.

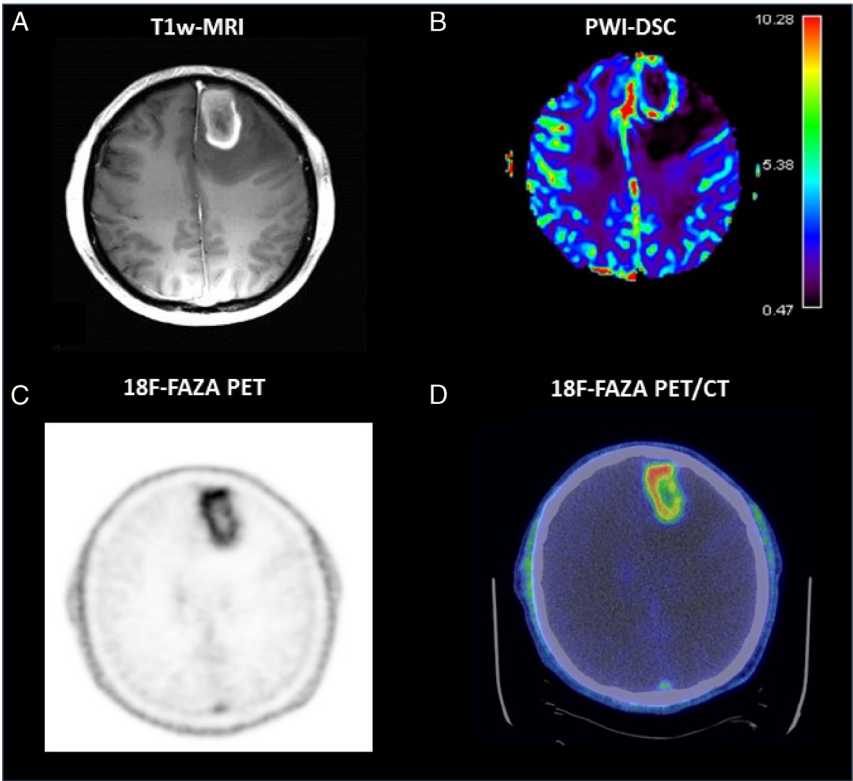


FIGURE 1. A 57-year-old man with behavioral disorders and headache underwent morphological and PWI-DSC MRI (A and B) showing a large edematous cystic necrotic enhancing frontal lesion (cerebral blood volume [CBV], 10.69) suggestive for high-grade glioma. As glioma was suspected, the patient signed an informed consent form for brain ^{18}F -FAZA PET/CT to identify tumor hypoxic regions. ^{18}F -FAZA PET/CT showed tracer uptake (SUV_{max} , 3.5; SUV_{mean} , 2.0; MTV40, 18.08; hypoxia volume, 16.69) in the left frontal brain lesion (C and D) with a central photopenic area, as per necrosis. A surgical excision of the tumor was performed; histological examination confirmed a glioblastoma, and genetic assessment showed no mutation for IDH1 and IDH2 with MGMT methylation.

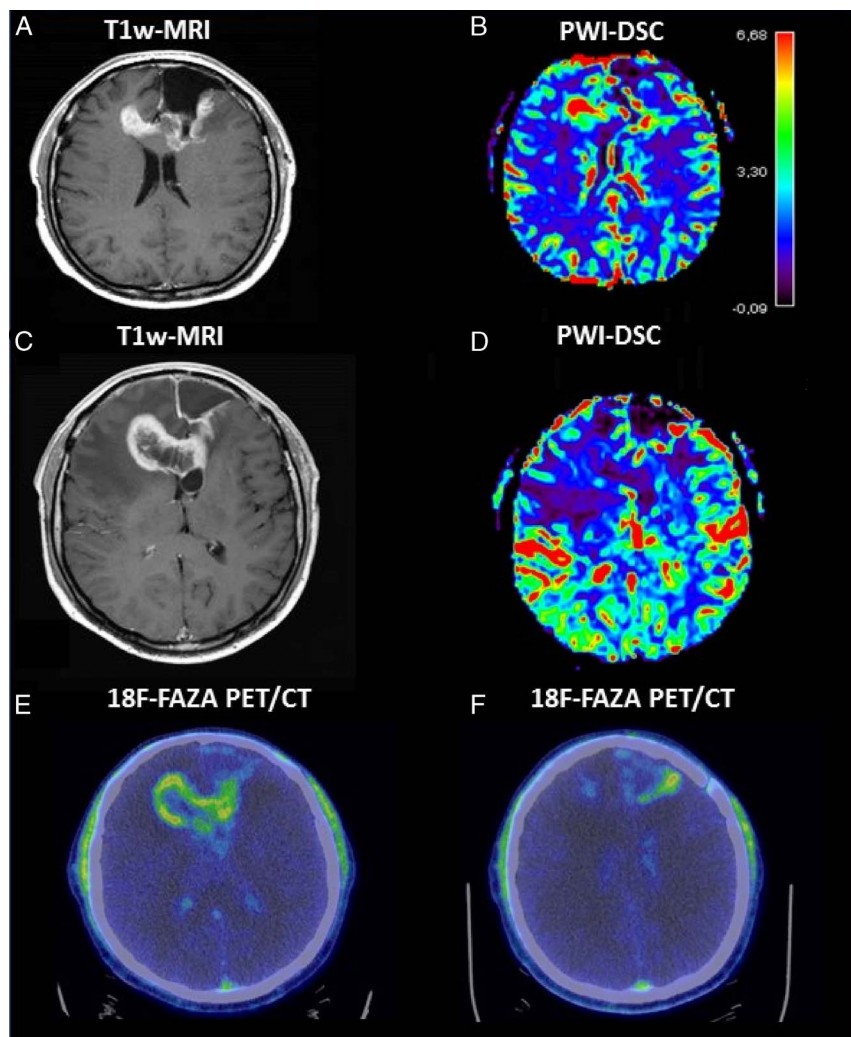


FIGURE 2. Postsurgical MRI and PWI-DSC study performed 1 month after surgery suggested progressive disease: a large enhanced area around surgical cavity and extending contralaterally (A) with CBV values showing high perfusion (B). The patient underwent adjuvant radiotherapy treatment with concomitant temozolomide, plus additional 14 monthly cycles of temozolomide. During treatment, a further brain MRI scan was performed showing a lesion enlargement as increment of edema (C) even if perfusion values (CBV, 13.72) seemed not suggestive for progression (D). As part of the aforementioned clinical protocol, a second ^{18}F -FAZA PET/CT scan was then performed for suspected recurrence. ^{18}F -FAZA PET/CT images showed increased ^{18}F -FAZA uptake in the right frontal region, suspicious for recurrence (E), with a peripheral uptake (SUV_{max} , 2.1; SUV_{mean} , 2.1; MTV_{40} , 35.60; hypoxia volume, 9.14) in correspondence of the surgical cavity (F), less intense compared with the basal scan. The patient continued the scheduled temozolomide cycles, and brain MRIs performed for treatment monitoring showed a progressive lesion reduction.

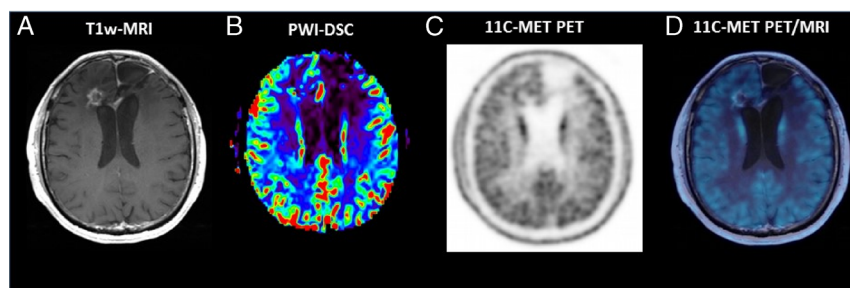


FIGURE 3. An MRI study performed after 2 years of disease stability showed the appearance of partial frontal lesion increment with areas of high perfusion. A ^{11}C -methionine (^{11}C -MET) PET/MRI was performed as per clinician's indication to better characterize the MRI finding. MR images showed partial frontal lesion increment (A) with areas of high perfusion (B) similar to the aforementioned MRI; no ^{11}C -MET radiotracer uptake (C, PET image; D, simultaneous PET/MR image) was detected; therefore, no evidence of disease was diagnosed on PET images. Contrast-enhanced MRI is the criterion standard morphological techniques for investigating high-grade gliomas.^{1,2} Hypoxia and amino acid PET imaging are complementary to MRI, underlying the multitracers capability of PET in assessing different metabolic pathways, thus providing a detailed characterization of high-grade gliomas, especially in complex cases. As hypoxia hampers the sensitivity to radiochemotherapy, ^{18}F -FAZA can be of support by detecting intratumoral areas more resistant to treatment and therefore more inclined to recurrence^{3,4}; in addition, it might improve the discrimination between radionecrosis and recurrence.^{5,6} ^{11}C -MET is used during diagnosis to identify more aggressive tumors and during therapy monitoring by supporting MRI in differentiating areas of altered perfusion because of recurrence/progression or not.⁷ Simultaneous PET/MRI scanners offer the possibility to integrate morphological and functional information in a single session examination, thus resulting in a diagnostic improvement for both patients' comfort and clinical information.⁸